

1

The Human Body: An Orientation

WHAT

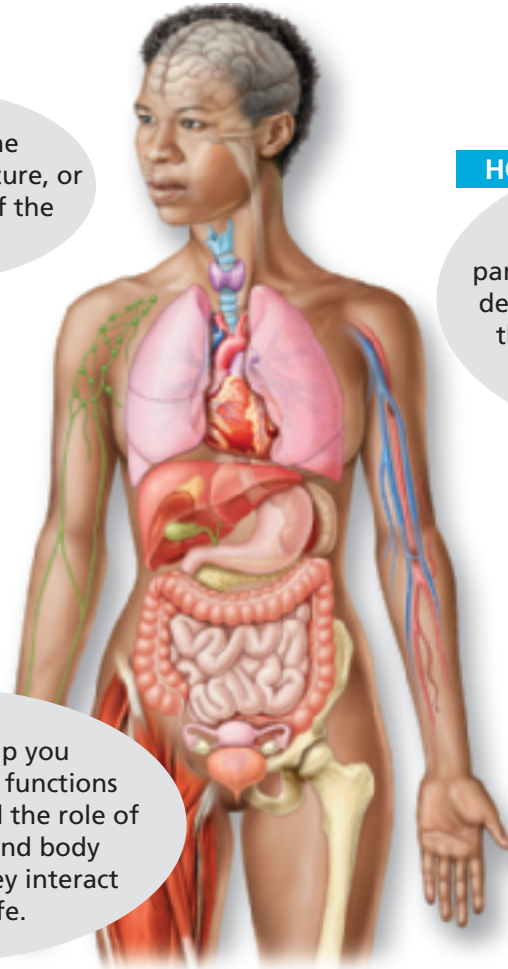Anatomy is the study of the structure, or physical form, of the body.

HOW

The function, or physiology, of each body part and the body as a whole is dependent on the anatomy of those parts; in other words, structure determines function.

WHY

This text will help you learn structures and functions so you can understand the role of individual organs and body systems and how they interact to support life.



INSTRUCTORS

New Building
Vocabulary Coaching
Activities for this
chapter are assignable
in MasteringA&P®

An Overview of Anatomy and Physiology

→ Learning Objectives

- Define *anatomy* and *physiology*.
- Explain how *anatomy* and *physiology* are related.

Most of us are naturally curious about our bodies; we want to know what makes us tick. Infants can keep themselves happy for a long time staring at their own hands or pulling their mother's nose. Older children wonder where food goes when they swallow it, and some believe that they will grow a watermelon in their belly if they swallow

the seeds. Adults become upset when their hearts pound, when they have uncontrollable hot flashes, or when they cannot keep their weight down.

Anatomy and physiology, subdivisions of biology, explore many of these topics as they describe how our bodies are put together and how they work.

Anatomy

Anatomy (ah-nat'ō-me) is the study of the structure and shape of the body and its parts and their relationships to one another. Whenever we look at our own body or study large body structures such as the heart or bones, we are observing *gross anatomy*;

that is, we are studying large, easily observable structures. Indeed, the term *anatomy*, derived from the Greek words meaning to cut (*tomy*) apart (*ana*), is related most closely to gross anatomical studies because in such studies, preserved animals or their organs are dissected (cut up) to be examined. *Microscopic anatomy*, in contrast, is the study of body structures that are too small to be seen with the naked eye. The cells and tissues of the body can only be seen through a microscope.

Physiology

Physiology (fiz"e-ol'o-je) is the study of how the body and its parts work or function (*physio* = nature; *ology* = the study of). Like anatomy, physiology has many subdivisions. For example, *neurophysiology* explains the workings of the nervous system, and *cardiac physiology* studies the function of the heart.

Relationship between Anatomy and Physiology

Anatomy and physiology are always inseparable. The parts of your body form a well-organized unit, and each of those parts has a job to do to make the body operate as a whole. Structure determines what functions can take place. For example, the lungs are not muscular chambers like the heart and so cannot pump blood through the body, but because the walls of their air sacs are very thin, they *can* exchange gases and provide oxygen to the body. We stress the intimate relationship between anatomy and physiology throughout this text to make your learning meaningful.

Did You Get It?

1. Why would you have a hard time learning and understanding physiology if you did not also understand anatomy?
2. Kidney function, bone growth, and beating of the heart are all topics of anatomy. True or false?

For answers, see Appendix A.

CONCEPTLINK

Throughout this text, Concept Links will highlight links between concepts and/or organ systems. Keep in mind that although discussions of the systems are separated into chapters for detailed study, the overall goal of this text is for you not only to gain an understanding of each individual system, but also to learn how the body systems interact to sustain life. ←

Levels of Structural Organization

→ Learning Objectives

- Name the six levels of structural organization that make up the human body, and explain how they are related.
- Name the organ systems of the body, and briefly state the major functions of each system.
- Identify and classify by organ system all organs discussed.

From Atoms to Organisms

The human body exhibits many levels of structural complexity (Figure 1.1). The simplest level of the structural ladder is the *chemical level* (covered in Chapter 2). At this level, **atoms**, tiny building blocks of matter, combine to form *molecules* such as water, sugar, and proteins, like those that make up our muscles. Molecules, in turn, associate in specific ways to form microscopic **cells**, the smallest units of all living things. (We will examine the *cellular level* in Chapter 3.) All cells have some common structures and functions, but individual cells vary widely in size, shape, and their particular roles in the body.

The simplest living creatures are composed of single cells, but in complex organisms such as trees or human beings, the structural ladder continues on to the *tissue level*. **Tissues** consist of groups of similar cells that have a common function. There are four basic tissue types, and each plays a definite but different role in the body. (We discuss tissues in Chapter 3.)

An **organ** is a structure composed of two or more tissue types that performs a specific function for the body. At the *organ level* of organization, extremely complex functions become possible. For example, the small intestine, which digests and absorbs food, is composed of all four tissue types. An **organ system** is a group of organs that work together to accomplish a common purpose. For example, the heart and blood vessels of the cardiovascular system circulate blood continuously to carry nutrients and oxygen to all body cells.

In all, 11 organ systems make up the living human being, or the **organism**, which represents the highest level of structural organization, the *organismal level*. The organismal level is the sum total of all structural levels working together to keep us alive. The major organs of each system

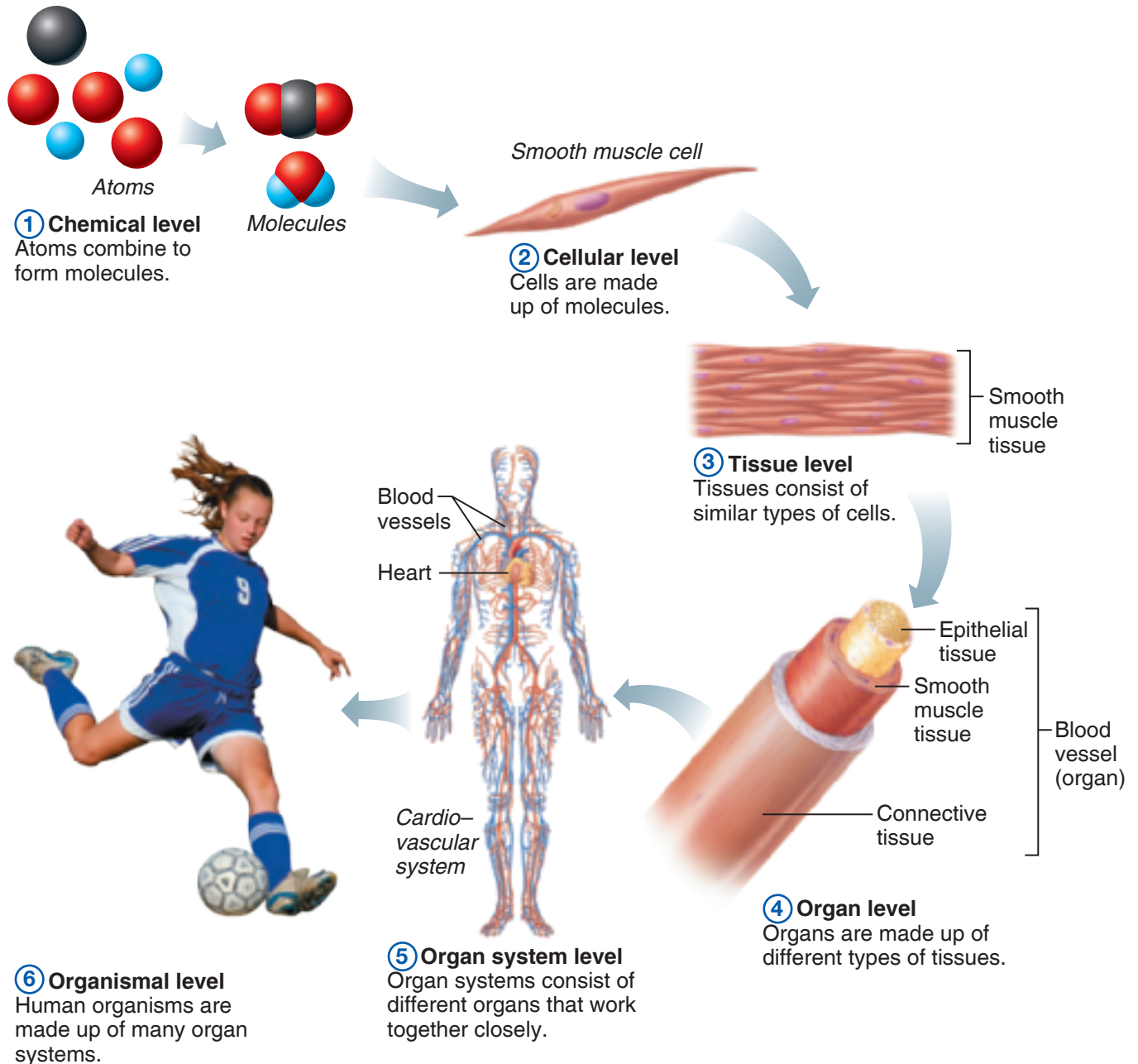


Figure 1.1 Levels of structural organization. In this diagram, components of the cardiovascular system are used to illustrate the levels of structural organization in a human being.

are shown in **Figure 1.2** on pp. 5–6. Refer to the figure as you read through the following descriptions of the organ systems.

Organ System Overview

Integumentary System

The **integumentary** (in-teg'ū-men'tar-e) **system** is the external covering of the body, or the skin, including the hair and fingernails (Figure 1.2a). It

waterproofs the body and cushions and protects the deeper tissues from injury. With the help of sunlight, it produces vitamin D. It also excretes salts in perspiration and helps regulate body temperature. Sensory receptors located in the skin alert us to what is happening at the body surface.

Skeletal System

The **skeletal system** consists of bones, cartilages, and joints (Figure 1.2b). It supports the body and

provides a framework that the skeletal muscles use to cause movement. It also has protective functions (for example, the skull encloses and protects the brain), and the cavities of the skeleton are the sites where blood cells are formed. The hard substance of bones acts as a storehouse for minerals.

Muscular System

The muscles of the body have only one function—to *contract*, or shorten. When this happens, movement occurs. The mobility of the body as a whole reflects the activity of *skeletal muscles*, the large, fleshy muscles attached to bones (Figure 1.2c). When these contract, you are able to stand erect, walk, jump, grasp, throw a ball, or smile. The skeletal muscles form the **muscular system**. These muscles are distinct from the muscles of the heart and of other hollow organs, which move fluids (such as blood or urine) or other substances (such as food) along definite pathways within the body.

Nervous System

The **nervous system** is the body's fast-acting control system. It consists of the brain, spinal cord, nerves, and sensory receptors (Figure 1.2d). The body must be able to respond to stimuli coming from outside the body (such as light, sound, or changes in temperature) and from inside the body (such as decreases in oxygen or stretching of tissue). The *sensory receptors* detect changes in temperature, pressure, or light, and send messages (via electrical signals called *nerve impulses*) to the central nervous system (brain and spinal cord) so that it is constantly informed about what is going on. The central nervous system then assesses this information and responds by activating the appropriate body *effectors* (muscles or glands, which are organs that produce secretions).

Endocrine System

Like the nervous system, the **endocrine system** (en'do-krin) controls body activities, but it acts much more slowly. *Endocrine glands* produce chemical molecules called *hormones* and release them into the blood to travel to relatively distant target organs.

The endocrine glands include the pituitary, thyroid, parathyroids, adrenals, thymus, pancreas, pineal, ovaries (in the female), and testes (in the male) (Figure 1.2e). The endocrine glands are not connected anatomically in the same way that the parts of other organ systems are. What they have

in common is that they all secrete hormones, which regulate other structures. The body functions controlled by hormones are many and varied, involving every cell in the body. Growth, reproduction, and the use of nutrients by cells are all controlled (at least in part) by hormones.

Cardiovascular System

The primary organs of the **cardiovascular system** are the heart and blood vessels (Figure 1.2f). Using blood as a carrier, the cardiovascular system delivers oxygen, nutrients, hormones, and other substances to, and picks up wastes such as carbon dioxide from, cells near sites of exchange. White blood cells and chemicals in the blood help to protect the body from such foreign invaders as bacteria, viruses, and tumor cells. The heart propels blood out of its chambers into blood vessels to be transported to all body tissues.

Lymphatic System

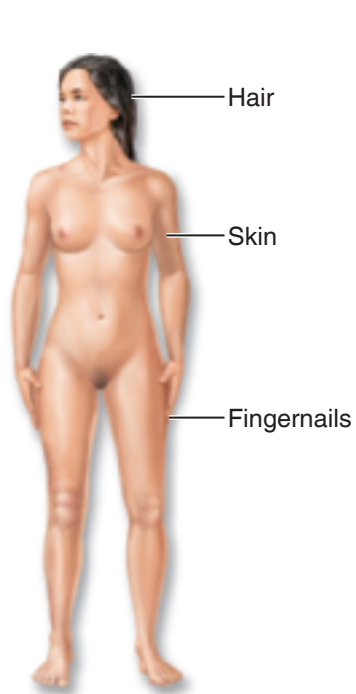
The role of the **lymphatic system** complements that of the cardiovascular system. Its organs include lymphatic vessels, lymph nodes, and other lymphoid organs such as the spleen and tonsils (Figure 1.2g). When fluid is leaked into tissues from the blood, lymphatic vessels return it to the bloodstream so that there is enough blood to continuously circulate through the body. The lymph nodes and other lymphoid organs help to cleanse the blood and house white blood cells involved in immunity.

Respiratory System

The job of the **respiratory system** is to keep the body supplied with oxygen and to remove carbon dioxide. The respiratory system consists of the nasal passages, pharynx, larynx, trachea, bronchi, and lungs (Figure 1.2h). Within the lungs are tiny air sacs. Gases are exchanged with the blood through the thin walls of these air sacs.

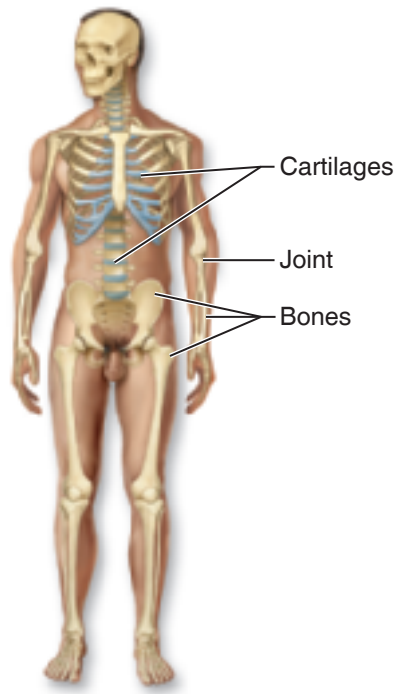
Digestive System

The **digestive system** is basically a tube running through the body from mouth to anus. The organs of the digestive system include the oral cavity (mouth), esophagus, stomach, small and large intestines, and rectum plus a number of accessory organs (liver, salivary glands, pancreas, and others) (Figure 1.2i). Their role is to break down food and deliver the resulting nutrients to the blood for dispersal to body cells. The breakdown activities



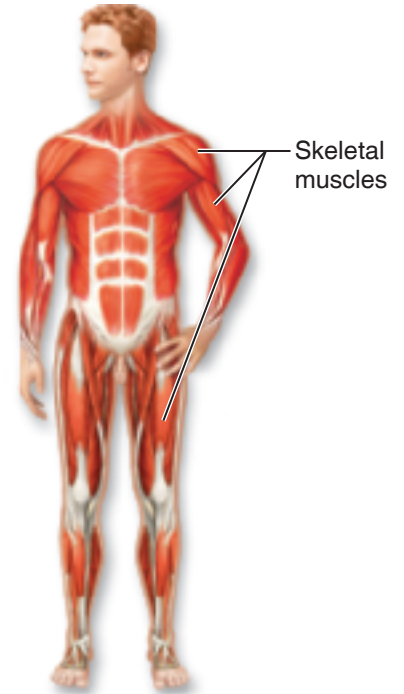
(a) Integumentary System

Forms the external body covering; protects deeper tissue from injury; synthesizes vitamin D; location of sensory receptors (pain, pressure, etc.) and sweat and oil glands.



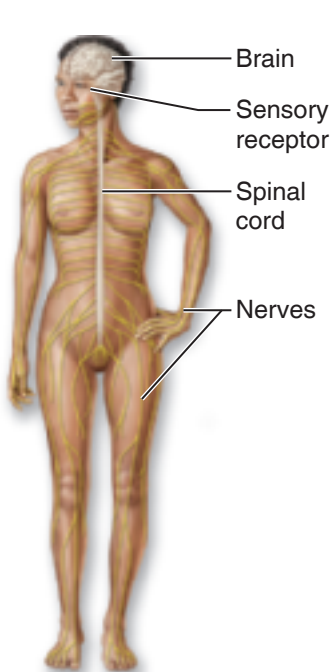
(b) Skeletal System

Protects and supports body organs; provides a framework the muscles use to cause movement; blood cells are formed within bones; stores minerals.



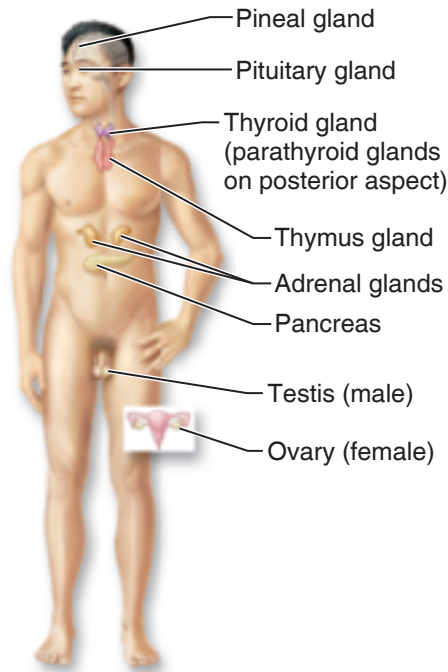
(c) Muscular System

Allows manipulation of the environment, locomotion, and facial expression; maintains posture; produces heat.



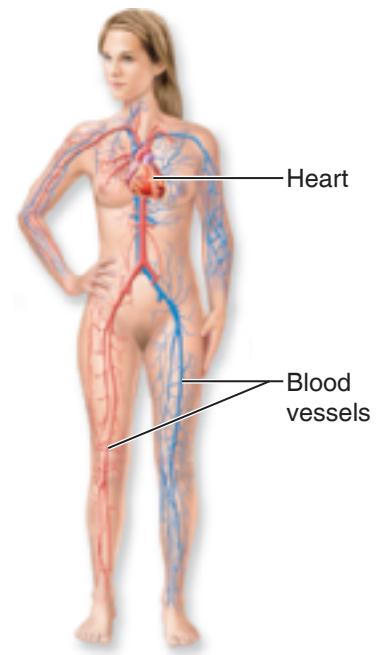
(d) Nervous System

Fast-acting control system of the body; responds to internal and external changes by activating appropriate muscles and glands.



(e) Endocrine System

Glands secrete hormones that regulate processes such as growth, reproduction, and nutrient use by body cells.

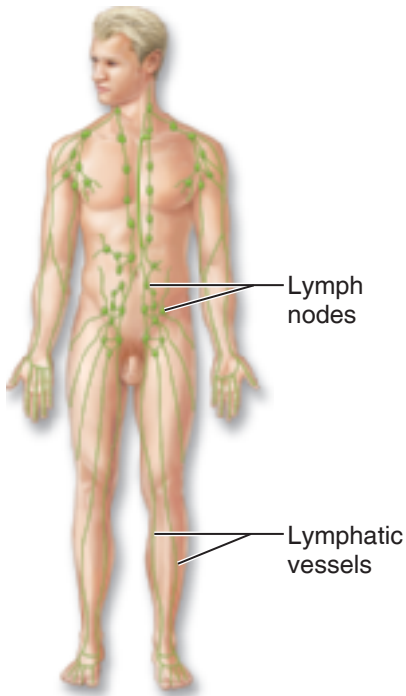


(f) Cardiovascular System

Blood vessels transport blood, which carries oxygen, nutrients, hormones, carbon dioxide, wastes, etc.; the heart pumps blood.

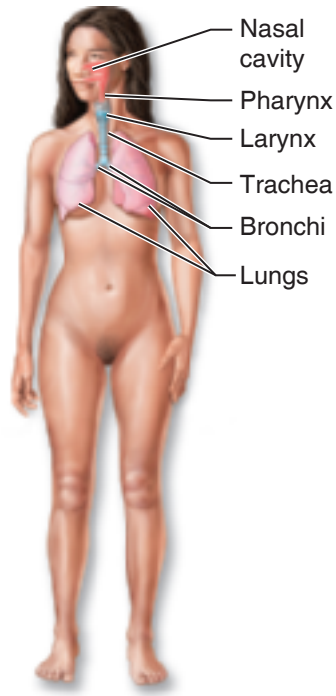
Figure 1.2 The body's organ systems.

(Figure continues on page 6.)



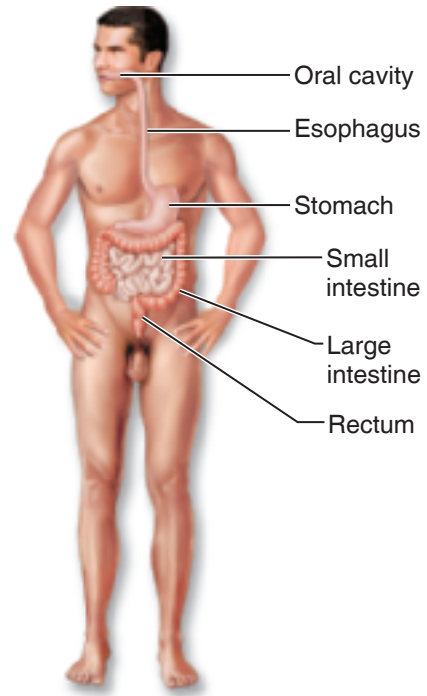
(g) Lymphatic System

Picks up fluid leaked from blood vessels and returns it to blood; disposes of debris in the lymphatic stream; houses white blood cells involved in immunity.



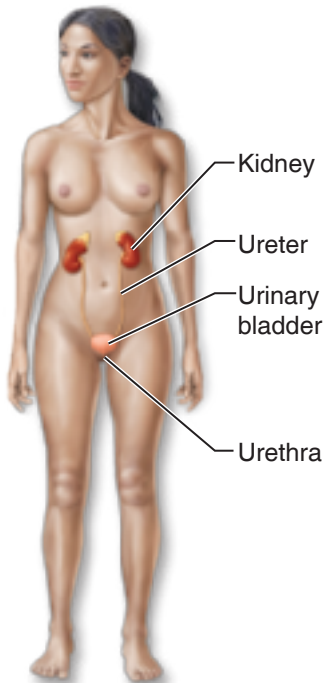
(h) Respiratory System

Keeps blood constantly supplied with oxygen and removes carbon dioxide; the gaseous exchanges occur through the walls of the air sacs of the lungs.



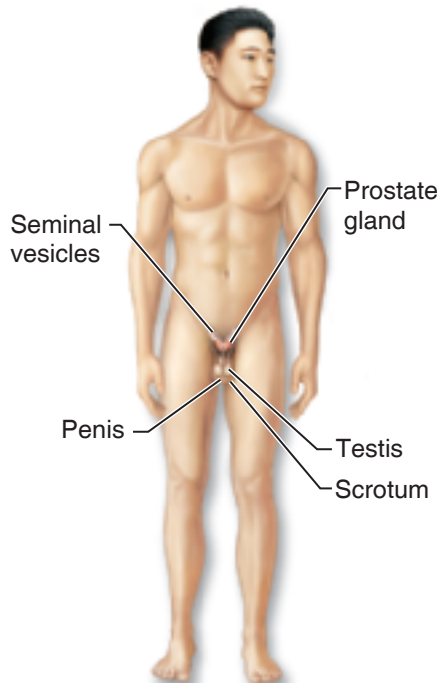
(i) Digestive System

Breaks food down into absorbable nutrients that enter the blood for distribution to body cells; indigestible foodstuffs are eliminated as feces.



(j) Urinary System

Eliminates nitrogen-containing wastes from the body; regulates water, electrolyte, and acid-base balance of the blood.



(k) Male Reproductive System (l) Female Reproductive System

Overall function of the reproductive system is production of offspring. Testes produce sperm and male sex hormone; ducts and glands aid in delivery of viable sperm to the female reproductive tract. Ovaries produce eggs and female sex hormones; remaining structures serve as sites for fertilization and development of the fetus. Mammary glands of female breasts produce milk to nourish the newborn.

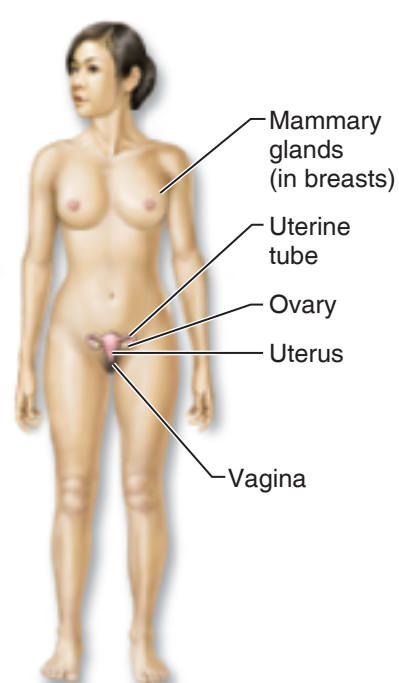


Figure 1.2 (continued) The body's organ systems.

that begin in the mouth are completed in the small intestine. From that point on, the major function of the digestive system is to reabsorb water. The undigested food that remains in the tract leaves the body through the anus as feces. The liver is considered a digestive organ because the bile it produces helps to break down fats. The pancreas, which delivers digestive enzymes to the small intestine, has both endocrine and digestive functions.

Urinary System

A normal part of healthy body function is the production of waste by-products, which must be disposed of. One type of waste contains nitrogen (examples are urea and uric acid), which results when the body cells break down proteins and nucleic acids, which are genetic information molecules. The **urinary system** removes the nitrogen-containing wastes from the blood and flushes them from the body in *urine*. This system, often called the *excretory system*, is composed of the kidneys, ureters, bladder, and urethra (Figure 1.2j). Other important functions of this system include maintaining the body's water and salt (electrolyte) balance, regulating the acid-base balance of the blood, and helping to regulate normal blood pressure.

Reproductive System

The role of the **reproductive system** is to produce offspring. The male testes produce sperm. Other male reproductive system structures are the scrotum, penis, accessory glands, and the duct system, which carries sperm to the outside of the body (Figure 1.2k). The female ovaries produce eggs, or ova; the female duct system consists of the uterine tubes, uterus, and vagina (Figure 1.2l). The uterus provides the site for the development of the fetus (immature infant) once fertilization has occurred.

Did You Get It?

3. At which level of structural organization is the stomach? At which level is a glucose molecule?
4. Which organ system includes the trachea, lungs, nasal cavity, and bronchi?
5. Which system functions to remove wastes and help regulate blood pressure?

For answers, see Appendix A.

Maintaining Life

→ Learning Objectives

- List eight functions that humans must perform to maintain life.
- List the five survival needs of the human body.

Necessary Life Functions

Now that we have introduced the structural levels composing the human body, a question naturally follows: What does this highly organized human body do? Like all complex animals, human beings maintain their boundaries, move, respond to environmental changes, take in and digest nutrients, carry out metabolism, dispose of wastes, reproduce themselves, and grow.

Organ systems do not work in isolation; instead, they work together to promote the well-being of the entire body (Figure 1.3). Because this theme is emphasized throughout this text, it is worthwhile to identify the most important organ systems contributing to each of the necessary life functions. Also, as you study this figure, you may want to refer to the more detailed descriptions of the organ systems just provided (pp. 3–7 and in Figure 1.2).

Maintaining Boundaries

Every living organism must be able to maintain its boundaries so that its “inside” remains distinct from its “outside.” Every cell of the human body is surrounded by an external membrane that separates its contents from the outside interstitial fluid (fluid between cells) and allows entry of needed substances while generally preventing entry of potentially damaging or unnecessary substances. The body as a whole is also enclosed by the integumentary system, or skin. The integumentary system protects internal organs from drying out (which would be fatal), from pathogens, and from the damaging effects of heat, sunlight, and an unbelievable number of chemical substances in the external environment.

Movement

Movement includes all the activities promoted by the muscular system, such as propelling ourselves from one place to another (by walking, swimming, and so forth) and manipulating the external environment with our fingers. The skeletal system provides the bones that the muscles pull on as they work. Movement also occurs when substances such as blood, foodstuffs, and urine

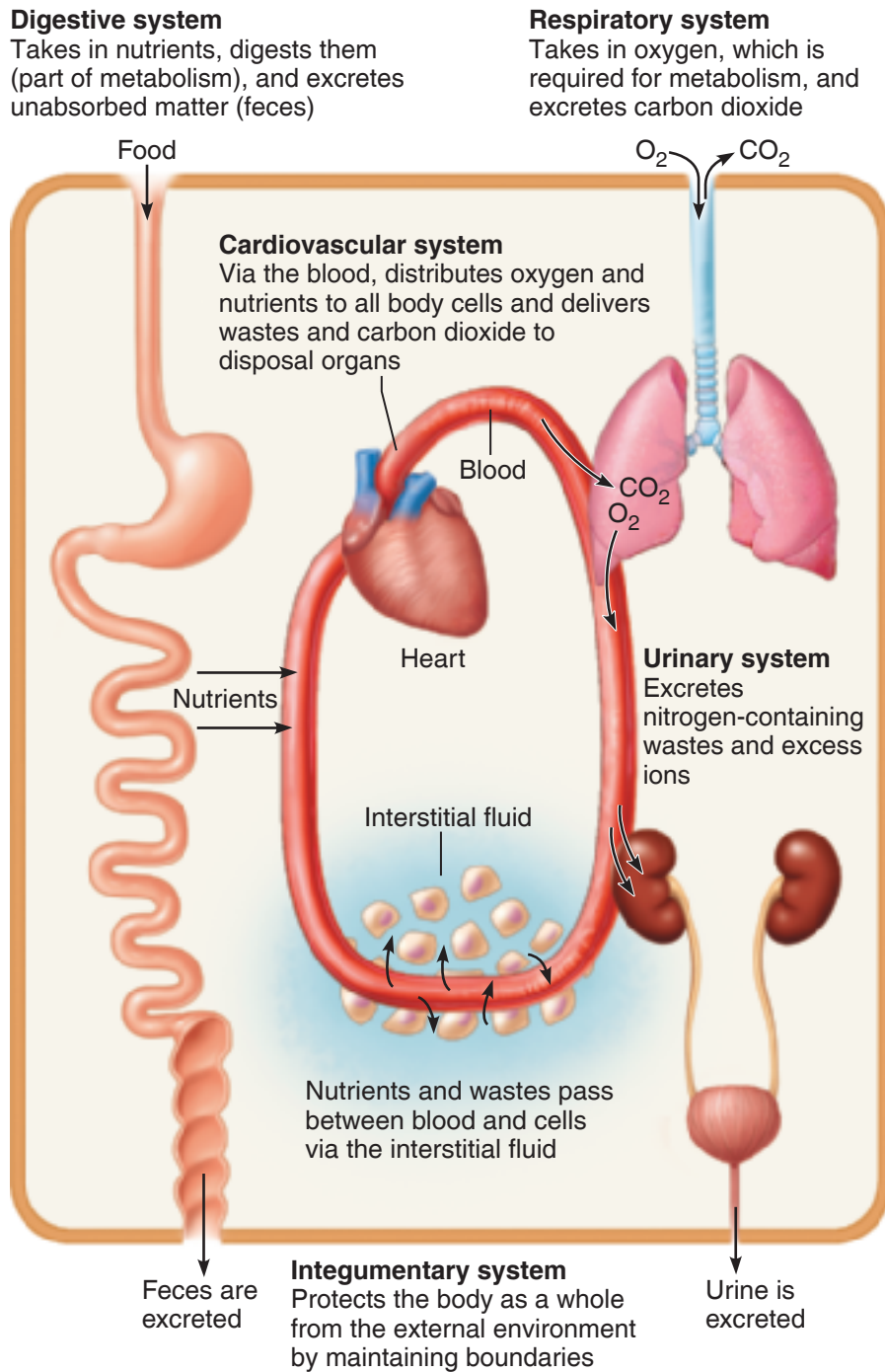


Figure 1.3 Examples of interrelationships among organ systems that illustrate life functions.

are propelled through the internal organs of the cardiovascular, digestive, and urinary systems, respectively.

Responsiveness

Responsiveness, or **irritability**, is the ability to sense changes (stimuli) in the environment and then to react to them. For example, if you accidentally touch a hot pan, you involuntarily pull your hand away from the painful stimulus (the

pan). You do not need to think about it—it just happens! Likewise, when the amount of carbon dioxide in your blood rises to a dangerously high level, your breathing rate speeds up to blow off the excess carbon dioxide.

Because nerve cells are highly irritable and can communicate rapidly with each other via electrical impulses, the nervous system bears the major responsibility for responsiveness. However, all body cells are responsive to some extent.

Digestion

Digestion is the process of breaking down ingested food into simple molecules that can then be absorbed into the blood. The nutrient-rich blood is then distributed to all body cells by the cardiovascular system, where body cells use these simple molecules for energy and raw materials.

Metabolism

Metabolism is a broad term that refers to all chemical reactions that occur within the body and all of its cells. It includes breaking down complex substances into simpler building blocks (as in digestion), making larger structures from smaller ones, and using nutrients and oxygen to produce molecules of *adenosine triphosphate (ATP)*, the energy-rich molecules that power cellular activities. Metabolism depends on the digestive and respiratory systems to make nutrients and oxygen available to the blood and on the cardiovascular system to distribute these needed substances throughout the body. Metabolism is regulated chiefly by hormones secreted by the glands of the endocrine system.

Excretion

Excretion is the process of removing *excreta* (ek-skre'tah), or wastes, from the body. Several organ systems participate in excretion. For example, the digestive system rids the body of indigestible food residues in feces, the urinary system disposes of nitrogen-containing metabolic wastes in urine, and the skin disposes of various waste products as components of sweat.

Reproduction

Reproduction, the production of offspring, can occur on the cellular or organismal level. In cellular reproduction, the original cell divides, producing two identical daughter cells that may then be used for body growth or repair. Reproduction of the human organism is the task of the organs of the reproductive system, which produce sperm and eggs. When a sperm unites with an egg, a fertilized egg forms, which then develops into a baby within the mother's body. The function of the reproductive system is regulated very precisely by hormones of the endocrine system.

Growth

Growth can be an increase in cell size or an increase in body size that is usually accomplished

by an increase in the number of cells. For growth to occur, cell-constructing activities must occur at a faster rate than cell-destroying ones. Hormones released by the endocrine system play a major role in directing growth.

Survival Needs

The goal of nearly all body systems is to maintain life. However, life is extraordinarily fragile and requires that several factors be available. These factors, which we will call *survival needs*, include nutrients (food), oxygen, water, and appropriate temperature and atmospheric pressure.

Nutrients, which the body takes in through food, contain the chemicals used for energy and cell building. *Carbohydrates* are the major energy-providing fuel for body cells. *Proteins* and, to a lesser extent, *fats* are essential for building cell structures. Fats also cushion body organs and provide reserve fuel. *Minerals* and *vitamins* are required for the chemical reactions that go on in cells and for oxygen transport in the blood.

All the nutrients in the world are useless unless **oxygen** is also available. Because the chemical reactions that release energy from foods require oxygen, human cells can survive for only a few minutes without it. It is made available to the blood and body cells by the cooperative efforts of the respiratory and cardiovascular systems.

Water accounts for 60 to 80 percent of body weight, depending on the age of the individual. It is the single most abundant chemical substance in the body and provides the fluid base for body secretions and excretions. We obtain water chiefly from ingested foods or liquids, and we lose it by evaporation from the lungs and skin and in body excretions.

If chemical reactions are to continue at life-sustaining levels, **normal body temperature** must be maintained. If body temperature drops below 37°C (98.6°F), metabolic reactions become slower and slower and finally stop. If body temperature is too high, chemical reactions proceed too rapidly, and body proteins begin to break down. At either extreme, death occurs. Most body heat is generated by the activity of the skeletal muscles and dissipated via blood circulating close to the skin surface or by the evaporation of sweat.

The force exerted on the surface of the body by the weight of air is referred to as **atmospheric pressure**. Breathing and the exchange of oxygen and carbon dioxide in the lungs depend on

(Text continues on page 12.)

Medical Imaging: Illuminating the Body

Imaging procedures are important diagnostic tools that are either minimally invasive or not invasive at all. By bombarding the body with different forms of energy, medical imaging techniques can reveal the structure of internal organs, show blood flow in real time, and even determine the density of bone.

Until about 50 years ago, the magical but murky X ray was the only means of peering into a living body without performing surgery. The X-ray film is a shadowy negative image of internal structures produced by directing electromagnetic waves of very short wavelength at the body. X rays are best used to visualize hard, bony structures and locate abnormally dense structures (tumors, tuberculosis nodules) in the lungs and breasts.

Two examples of low-dose X-ray procedures are mammography and bone densitometry. A **mammogram** is used to identify changes in breast tissue, including dense masses or calcifications. A mammogram is performed by compressing the breast in a special X-ray machine because thinner tissue results in a better image; see photo (a). **Bone densitometry** detects the amount of calcium and minerals stored in bone and is the major diagnostic test for osteoporosis; see photo (b).

The 1950s saw the birth of **ultrasound imaging (ultrasonography)**, which has some distinct advantages over other imaging techniques. The equipment employs high-frequency sound waves (ultrasound) as its energy source. Unlike X rays, ultrasound has no known harmful effects on living tissues. The

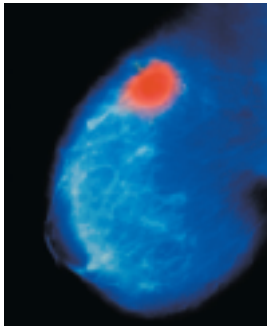
body is probed with pulses of sound waves, which cause echoes when reflected and scattered by body tissues. The echoes are analyzed by computer to construct visual images of body organs, much like sonar is used to map the ocean floor. Because of its safety, ultrasound is the imaging technique of choice for determining fetal age and position and locating the placenta; see photo (c). Because sound waves have very low penetrating power and are rapidly scattered in air, sonography does not visualize air-filled structures (the lungs) or those surrounded by bone (the brain and spinal cord) well.

Though nuclear medicine, which uses radioisotopes to scan the body, was developed in the 1950s, it was not until the 1970s that a powerful technique for visualizing metabolic activities, PET, was introduced. The 1970s also introduced CT, an X-ray-based scanning technique, and MRI scanning techniques, which use powerful magnets.

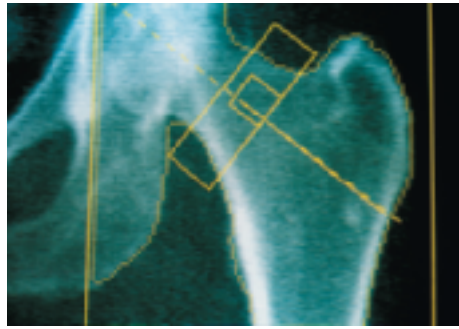
Positron emission tomography (PET) requires an injection of short-lived radioisotopes that have been tagged to biological molecules (such as glucose) in order to view metabolic processes. The patient is positioned in the PET scanner, and as the radioisotopes are absorbed by the most active brain cells, high-energy gamma rays are produced. A computer analyzes the gamma emissions and produces a picture of the brain's biochemical activity in vivid colors. PET's greatest clinical value has been its ability to provide insights into brain activity in people affected by mental illness, Alzheimer's disease, and epilepsy.

Currently PET can reveal signs of trouble in people with undiagnosed Alzheimer's disease (AD) because regions of beta-amyloid accumulation (a defining characteristic of AD) show up in brilliant red and yellow when that molecule is tagged. By tagging glucose, we can observe that brain tissue in areas of impairment or areas with Alzheimer's plaques use far less glucose compared to normal brain tissue as shown in photo (d).

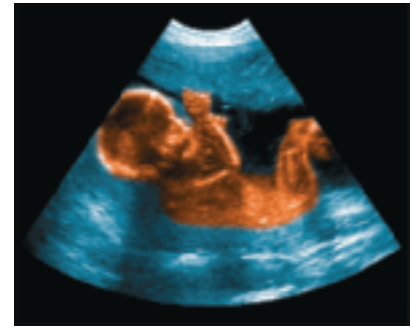
Perhaps the best known of these newer imaging devices is **computed tomography (CT)**, a refined version of X ray that eliminates the confusion resulting from images of overlapping structures. A CT scanner takes "pictures" of a thin slice of the body, about as thick as a dime. Different tissues absorb the radiation in varying amounts. The device's computer translates this information into a detailed, cross-sectional picture of the body region scanned; see photo (e). CT scans are at the forefront in evaluating most problems that affect the brain and abdomen, and their clarity has all but eliminated exploratory surgery. Special ultrafast CT scanners have produced a technique called **dynamic spatial reconstruction (DSR)**, which provides three-dimensional images of body organs from any angle. It also allows organ movements and changes in internal volumes to be observed at normal speed, in slow motion, and at a specific moment in time. The greatest value of DSR has been to visualize the heart beating and blood flowing through blood vessels. This allows medical personnel to assess heart defects, constricted blood vessels, and the status of coronary bypass grafts.



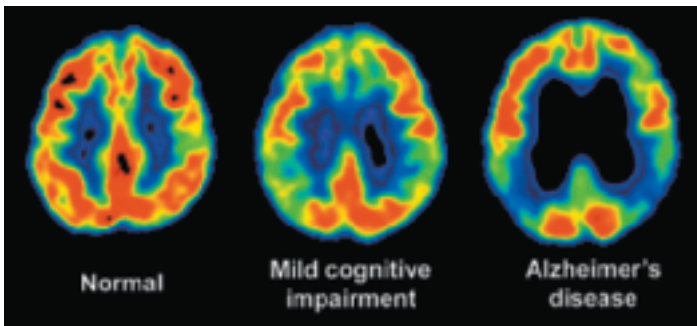
(a) Mammogram showing breast cancer.



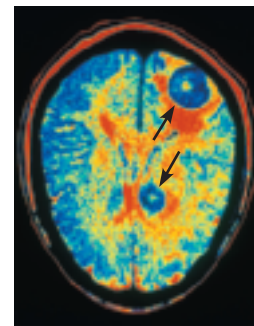
(b) Bone densitometry scan showing osteoporosis in the small yellow box on the neck of the femur.



(c) Sonogram of a fetus.



(d) A PET scan demonstrates glucose metabolism in a normal brain (*left*). Glucose metabolism is decreased in a brain with mild cognitive impairment (*middle*), and glucose is metabolized at an even lower level in a brain with Alzheimer's plaques (*right*).



(e) CT scan showing brain tumors (indicated by black arrows).

A different technique is **magnetic resonance imaging (MRI)**, which uses magnetic fields up to 60,000 times stronger than Earth's to pry information from body tissues. The patient lies in a tubelike chamber within a huge magnet. Hydrogen molecules spin like tops in the magnetic field, and their energy is enhanced by the presence of radio waves. When the radio waves are turned off, energy is released and translated by a computer into a visual image (see Figure 1.5, p. 16). MRI is immensely popular because it can do many things a CT scan cannot. Dense structures do not show up in MRI, so bones of the skull and/or vertebral

column do not impair the view of *soft tissues*, such as the brain or intervertebral discs, the cartilage pads between vertebrae. MRI is also particularly good at detecting signs of degenerative disease such as multiple sclerosis plaques, which do not show up well in CT scans but are dazzlingly clear in MRI scans.

A variation of MRI called **functional magnetic resonance imaging (fMRI)** allows tracking of blood flow into the brain in real time. Before 1992, PET was the only way to match brain activity to disease. With no need for injections of radioisotopes, fMRI provides a less invasive alternative. Despite its advantages,

the powerful magnets of the MRI can pose risks. For example, metal objects, such as implanted pacemakers and loose tooth fillings, can be "sucked" through the body. Also, the long-term health risks of exposure to strong magnetic fields are not clear.

As you can see, modern medical science enlists remarkable diagnostic tools. CT and PET scans account for about 25 percent of all imaging. Ultrasonography, because of its safety and low cost, is the most widespread. However, conventional X rays remain the workhorse of diagnostic imaging and still account for more than half of all medical imaging.

appropriate atmospheric pressure. At high altitudes, where the air is thin and atmospheric pressure is lower, gas exchange may be too slow to support cellular metabolism.

The mere presence of these survival factors is not sufficient to maintain life. They must be present in appropriate amounts as well; excesses and deficits may be equally harmful. For example, the food ingested must be of high quality and in proper amounts; otherwise, nutritional disease, obesity, or starvation is likely.

Did You Get It?

6. In addition to being able to metabolize, grow, digest food, and excrete wastes, what other functions must an organism perform if it is to survive?
7. Oxygen is a survival need. Why is it so important? In which life function does oxygen participate directly?

For answers, see Appendix A.

The Language of Anatomy

→ Learning Objectives

- Verbally describe or demonstrate the anatomical position.
- Use proper anatomical terminology to describe body directions, surfaces, and body planes.
- Locate the major body cavities, and list the chief organs in each cavity.

Learning about the body is exciting, but it can get harder to maintain our interest when we are faced with all the new terminology of anatomy and physiology. Let's face it: You can't just pick up an anatomy and physiology book and read it as if it were a novel. Unfortunately, confusion is inevitable without specialized terminology. For example, if you are looking at a ball, "above" always means the area over the top of the ball. Other directional terms can also be used consistently because the ball is a sphere. All sides and surfaces are equal. The human body, of course, has many protrusions and bends. Thus, the question becomes: Above what? To prevent misunderstanding, anatomists use a set of terms that allow body structures to be located and identified clearly with just a few words. We present and explain this language of anatomy next.

Anatomical Position

To accurately describe body parts and position, we must have an initial reference point and use

directional terms. To avoid confusion, we always assume that the body is in a standard position called **anatomical position**. It is important to understand this position because most body terminology used in this text refers to this body positioning *regardless* of the position the body happens to be in. In the anatomical position, the body is erect with the feet parallel and the arms hanging at the sides with the palms facing forward. Stand up now, and assume the anatomical position. Notice that it is similar to "standing at attention" but is less comfortable because the palms are held unnaturally forward (with thumbs pointing away from the body) rather than hanging cupped toward the thighs.

Directional Terms

Directional terms allow medical personnel and anatomists to explain exactly where one body structure is in relation to another. For example, we can describe the relationship between the ears and the nose informally by saying, "The ears are located on each side of the head to the right and left of the nose." In anatomical terminology, this condenses to, "The ears are lateral to the nose." Using anatomical terminology saves words and, once learned, is much clearer. Commonly used directional terms are defined and illustrated in **Table 1.1**. Although most of these terms are also used in everyday conversation, keep in mind that their anatomical meanings are very precise.

Before continuing, check your understanding of what you have read in the table. Give the relationship between the following body parts using the correct anatomical terms.

The wrist is _____ to the hand.

The breastbone is _____ to the spine.

The brain is _____ to the spinal cord.

The thumb is _____ to the fingers.
(Be careful here. Remember the anatomical position.)

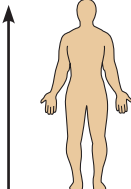
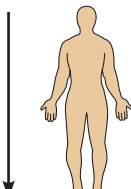


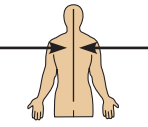
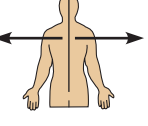
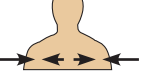
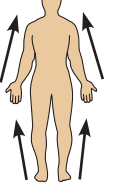
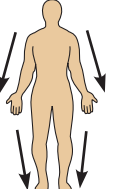


Regional Terms

There are many visible landmarks on the surface of the body. Once you know their proper anatomical names, you can be specific in referring to different regions of the body.

Anterior Body Landmarks

Look at **Figure 1.4a** to find the following body regions. Once you have identified all the anterior

Table 1.1 Orientation and Directional Terms

Term	Definition	Illustration	Example
Superior (cranial or cephalic)	Toward the head end or upper part of a structure or the body; above		The forehead is superior to the nose.
Inferior (caudal)*	Away from the head end or toward the lower part of a structure or the body; below		The navel is inferior to the breastbone.
Anterior (ventral)†	Toward or at the front of the body; in front of		The breastbone is anterior to the spine.
Posterior (dorsal)†	Toward or at the backside of the body; behind		The heart is posterior to the breastbone.
Medial	Toward or at the midline of the body; on the inner side of		The heart is medial to the arm.
Lateral	Away from the midline of the body; on the outer side of		The arms are lateral to the chest.
Intermediate	Between a more medial and a more lateral structure		The collarbone is intermediate between the breastbone and the shoulder.
Proximal	Close to the origin of the body part or the point of attachment of a limb to the body trunk		The elbow is proximal to the wrist (meaning that the elbow is closer to the shoulder or attachment point of the arm than the wrist is).
Distal	Farther from the origin of a body part or the point of attachment of a limb to the body trunk		The knee is distal to the thigh.
Superficial (external)	Toward or at the body surface		The skin is superficial to the skeleton.
Deep (internal)	Away from the body surface; more internal		The lungs are deep to the rib cage.

*The term caudal, literally "toward the tail," is synonymous with *inferior* only to the inferior end of the spine.

†*Anterior* and *ventral* are synonymous in humans, but not in four-legged animals. *Ventral* refers to an animal's "belly," making it the inferior surface. Likewise, posterior and dorsal surfaces are the same in humans, but *dorsal* refers to an animal's back, making it the superior surface.

Q: Study this figure for a moment to answer these two questions. Where would you hurt if you (1) pulled a groin muscle or (2) cracked a bone in your olecranal area?

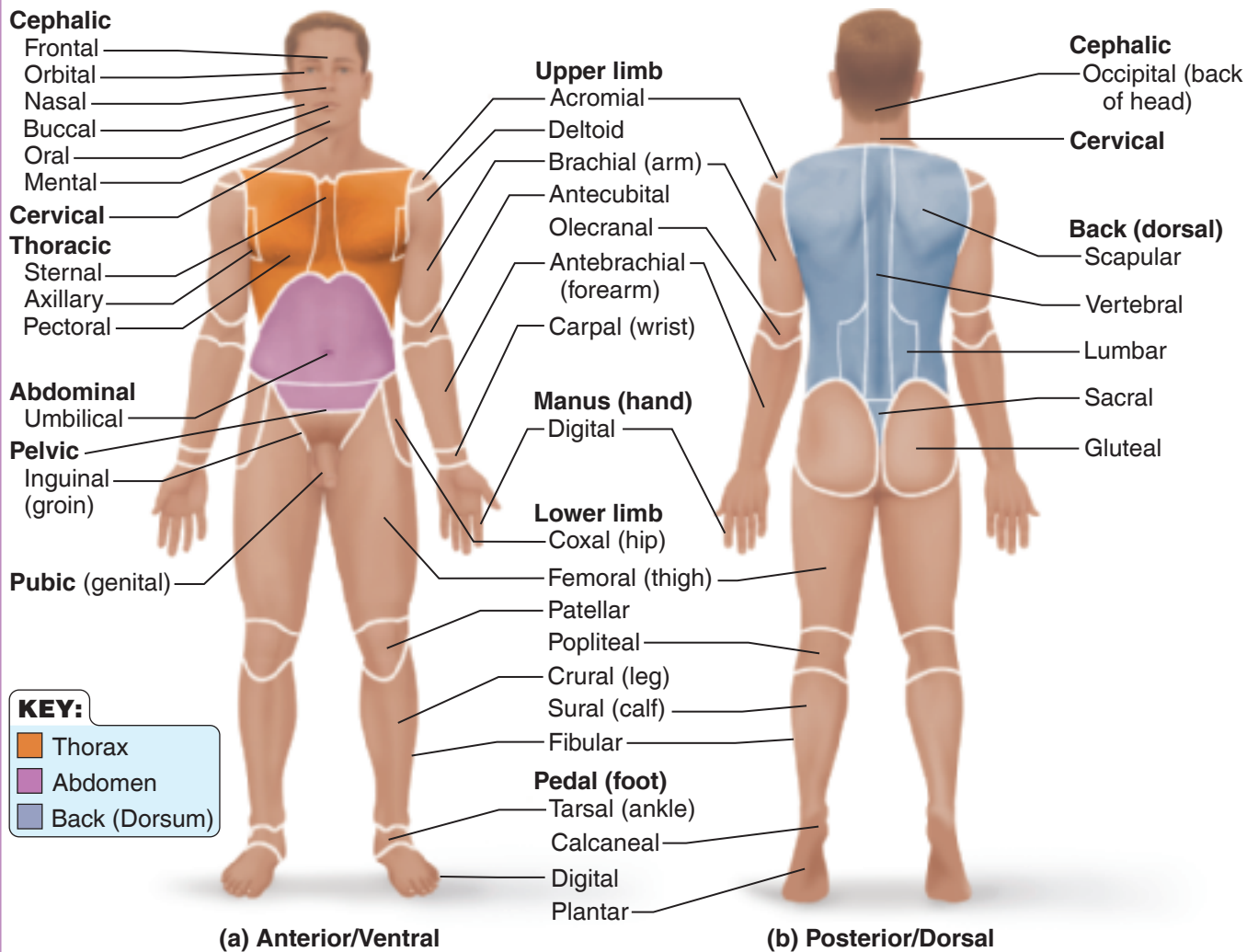


Figure 1.4 The anatomical position and regional terms. This figure shows terms used to designate specific body areas. **(a)** Anterior view. **(b)** Posterior view. The heels are raised slightly to show the inferior plantar surface (sole) of the foot, which is actually on the inferior surface of the body.

body landmarks, cover the labels that describe what the structures are. Then go through the list again, pointing out these areas on your own body.

- **abdominal** (ab-dom'i-nal): anterior body trunk inferior to ribs
- **acromial** (ah-kro'me-ul): point of shoulder
- **antebrachial** (an'te-bra'ke-al): forearm
- **antecubital** (an'te-ku'bi-tal): anterior surface of elbow

- **axillary** (ak'si-lar'e): armpit
- **brachial** (bra'ke-al): arm
- **buccal** (buk'al): cheek area
- **carpal** (kar'pal): wrist
- **cervical** (ser'vi-kal): neck region
- **coxal** (kok'sal): hip
- **crural** (kroo'ral): anterior leg; the shin.
- **deltoid** (del'toyd): curve of shoulder formed by large deltoid muscle
- **digital** (dij'i-tal): fingers, toes
- **femoral** (fem'or-al): thigh (applies to both anterior and posterior)

A: (1) Your inguinal region. (2) Your posterior elbow region.

- **fibular** (fib' u-lar): lateral part of leg
- **frontal** (frun'tal): forehead
- **inguinal** (in' gwī-nal): area where thigh meets body trunk; groin
- **mental** (men'tul): chin
- **nasal** (na'zul): nose area
- **oral** (o'ral): mouth
- **orbital** (or'bī-tal): eye area
- **patellar** (pah-tel'er): anterior knee
- **pectoral** (pek'to-ral): relating to, or occurring in or on, the chest
- **pelvic** (pel'vik): area overlying the pelvis anteriorly
- **pubic** (pyu'bik): genital region
- **sternal** (ster'nul): breastbone area
- **tarsal** (tar'sal): ankle region
- **thoracic** (tho-ras'ik): area between the neck and abdomen, supported by the ribs, sternum and costal cartilages; chest
- **umbilical** (um-bil' i-kal): navel

Posterior Body Landmarks

Identify the following body regions in Figure 1.4b, and then locate them on yourself without referring to this text.

- **calcaneal** (kal-ka'ne-ul): heel of foot
- **cephalic** (seh-fă'lik): head
- **femoral** (fem'or-al): thigh
- **gluteal** (gloo'te-al): buttock
- **lumbar** (lum'bar): area of back between ribs and hips; the loin
- **occipital** (ok-sip' i-tal): posterior surface of head or base of skull
- **olecranal** (ol-eh-kra'nel): posterior surface of elbow
- **popliteal** (pop-lit'e-al): posterior knee area
- **sacral** (sa'krul): area between hips at base of spine
- **scapular** (skap'u-lar): shoulder blade region
- **sural** (soo'ral): the posterior surface of leg; the calf
- **vertebral** (ver'tē-bral): area of spinal column

The **plantar** region, or the sole of the foot, actually on the inferior body surface, is illustrated with the posterior body landmarks (see Figure 1.4b).

Did You Get It?

8. What is the anatomical position, and why is it important that an anatomy student understand it?
9. The axillary and the acromial areas are both in the general area of the shoulder. To what specific body area does each of these terms apply?
10. Use anatomical language to describe the location of a cut to the back of your left forearm.

For answers, see Appendix A.

Body Planes and Sections

When preparing to look at the internal structures of the body, medical students make a **section**, or cut. When the section is made through the body wall or through an organ, it is made along an imaginary line called a **plane**. Because the body is three-dimensional, we can refer to three types of planes or sections that lie at right angles to one another (**Figure 1.5**).

A **sagittal** (saj' i-tal) **section** is a cut along the lengthwise, or longitudinal, plane of the body, dividing the body into right and left parts. If the cut is down the median plane of the body and the right and left parts are equal in size, it is called a **median (midsagittal) section**. All other sagittal sections are parasagittal sections (*para* = near).

A **frontal section** is a cut along a lengthwise plane that divides the body (or an organ) into anterior and posterior parts. It is also called a **coronal** (ko-ro'nal, “crown”) **section**.

A **transverse section** is a cut along a horizontal plane, dividing the body or organ into superior and inferior parts. It is also called a **cross section**.

Sectioning a body or one of its organs along different planes often results in very different views. For example, a transverse section of the body trunk at the level of the kidneys would show kidney structure in cross section very nicely; a frontal section of the body trunk would show a different view of kidney anatomy; and a midsagittal section would miss the kidneys completely. Information on body organ positioning can be gained by taking magnetic resonance imaging (MRI) scans along different body planes (see Figure 1.5). MRI scans are described further in “A Closer Look” (pp. 10–11).

Body Cavities

Anatomy and physiology textbooks typically describe two sets of internal body cavities, called the *dorsal* and *ventral body cavities*, that provide different degrees of protection to the organs

Q: Which section type would separate the two eyes?

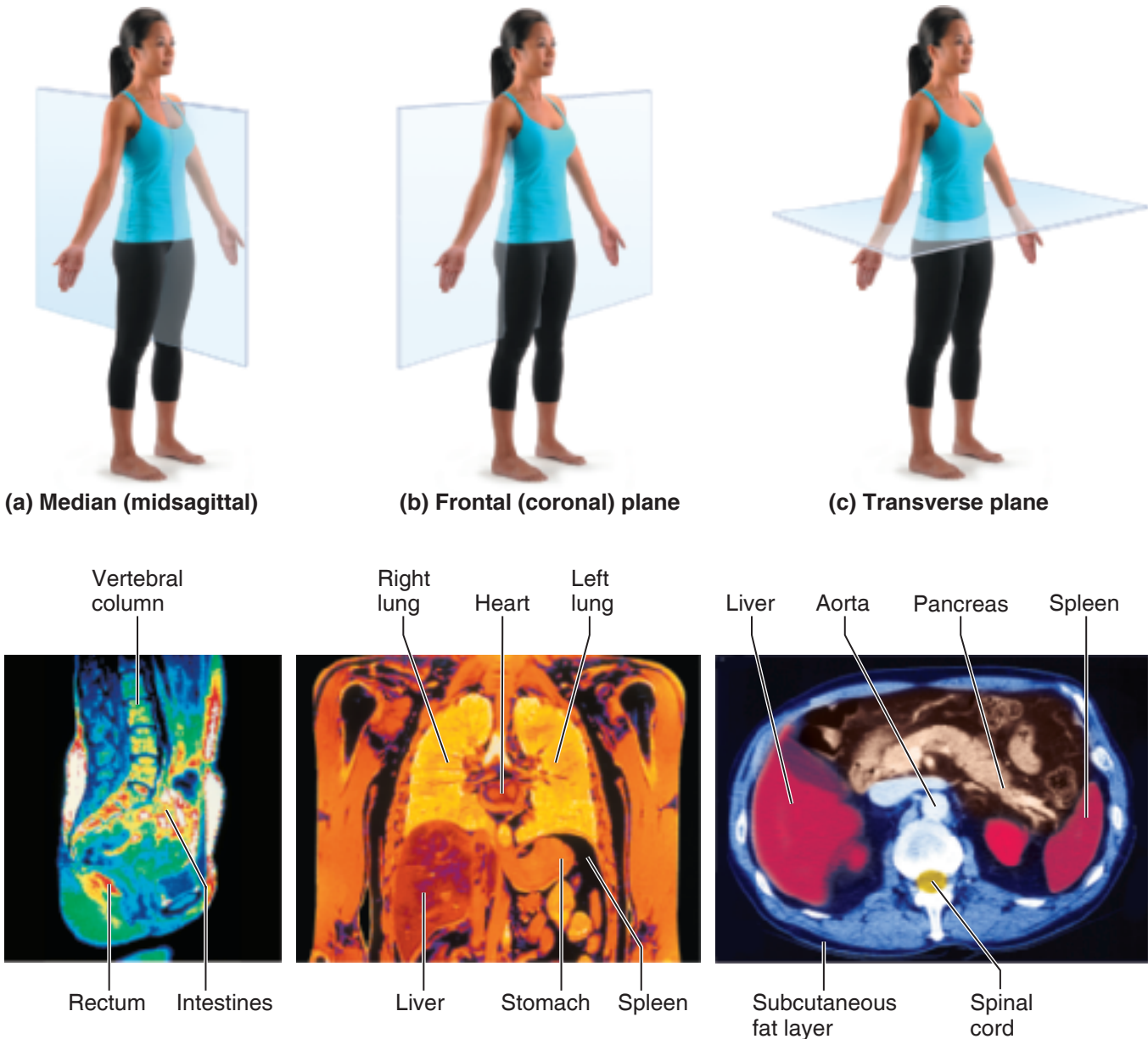


Figure 1.5 The planes of the body—median, frontal, and transverse—with corresponding MRI scans. Note that the planes are shown on a body in the anatomical position.

within them (**Figure 1.6**). Because these cavities differ in their mode of embryological development and in their lining membranes, many anatomy reference books do not identify the dorsal, or neural,

body cavity as an internal body cavity. However, the idea of two major sets of internal body cavities is a useful learning concept, so we will continue to use it here.

A: A midsagittal section would separate the two eyes.

Dorsal Body Cavity

The **dorsal body cavity** has two subdivisions, which are continuous with each other. The **cranial**

cavity is the space inside the bony skull. The brain is well protected because it occupies the cranial cavity. The **spinal cavity** extends from the cranial cavity to the end of the spinal cord. The spinal cord, which is a continuation of the brain, is protected by the bony vertebrae, which surround the spinal cavity and form the spine.

Ventral Body Cavity

The **ventral body cavity** is much larger than the dorsal cavity. It contains all the structures within the chest and abdomen, that is, the visceral organs in those regions. Like the dorsal cavity, the ventral body cavity is subdivided. The superior **thoracic cavity** is separated from the rest of the ventral cavity by a dome-shaped muscle, the **diaphragm** (di'ah-fram). The organs in the thoracic cavity (lungs, heart, and others) are protected by the rib cage. A central region called the **mediastinum** (me'de-as-ti'num) separates the lungs into right and left cavities in the thoracic cavity. The mediastinum itself houses the heart, trachea, and several other visceral organs.

The cavity inferior to the diaphragm is the **abdominopelvic** (ab-dom'i-no-pel'vik) **cavity**. Some prefer to subdivide it into a superior **abdominal cavity** containing the stomach, liver, intestines, and other organs, and an inferior **pelvic cavity** containing the reproductive organs, bladder, and rectum. However, there is no actual physical structure dividing the abdominopelvic cavity. The pelvic cavity is not immediately inferior to the abdominal cavity, but rather tips away from the abdominal cavity in the posterior direction (see Figure 1.6).

When the body is subjected to physical trauma (as often happens in an automobile accident, for example), the most vulnerable abdominopelvic organs are those within the abdominal cavity. The reason is that the abdominal cavity walls are formed only of trunk muscles and are not reinforced by bone. The pelvic organs receive some protection from the bony pelvis in which they reside.

Because the abdominopelvic cavity is quite large and contains many organs, it helps to divide it up into smaller areas for study. A scheme commonly used by medical personnel divides the abdominopelvic cavity into four more or less equal regions called *quadrants*. The quadrants are named according to their relative locations with respect to anatomical position—that is, right upper quadrant (RUQ), right lower quadrant (RLQ), left upper quadrant (LUQ), and left lower quadrant (LLQ) (Figure 1.7).

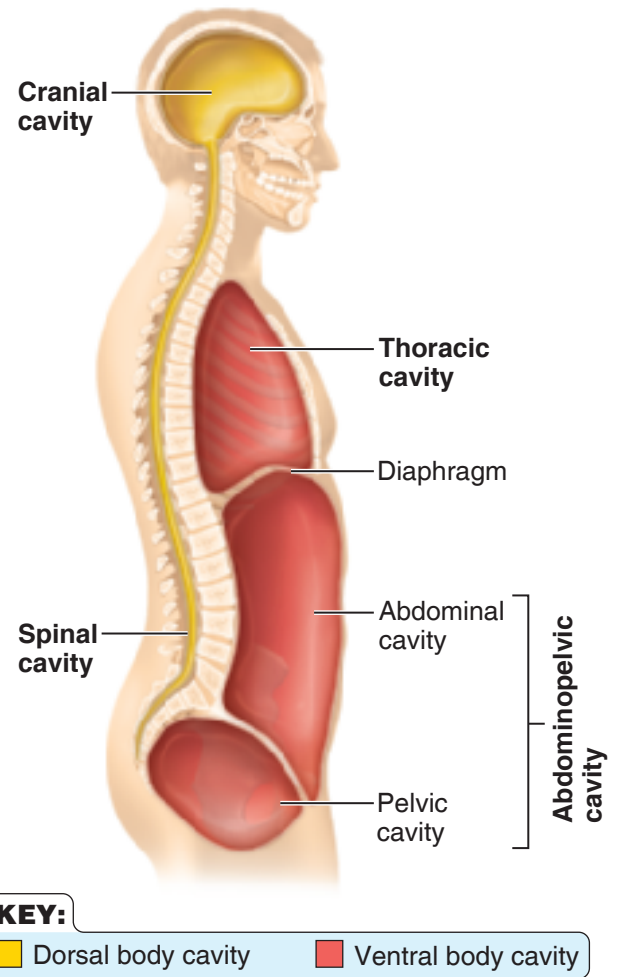


Figure 1.6 Body cavities. Notice the angular relationship between the abdominal and pelvic cavities.

Another system, used mainly by anatomists, divides the abdominopelvic cavity into nine separate *regions* by four planes (Figure 1.8a). As you locate these regions, notice the organs they contain (Figure 1.8b).

- The **umbilical region** is the centermost region, deep to and surrounding the umbilicus (navel).
- The **epigastric** (ep'i-gas'trik) **region** is located superior to the umbilical region (*epi* = upon, above; *gastric* = stomach).
- The **hypogastric (pubic) region** is inferior to the umbilical region (*hypo* = below).
- The **right iliac (inguinal) region** and **left iliac (inguinal) region** are lateral to the hypogastric region (*iliac* = superior part of the hip bone).

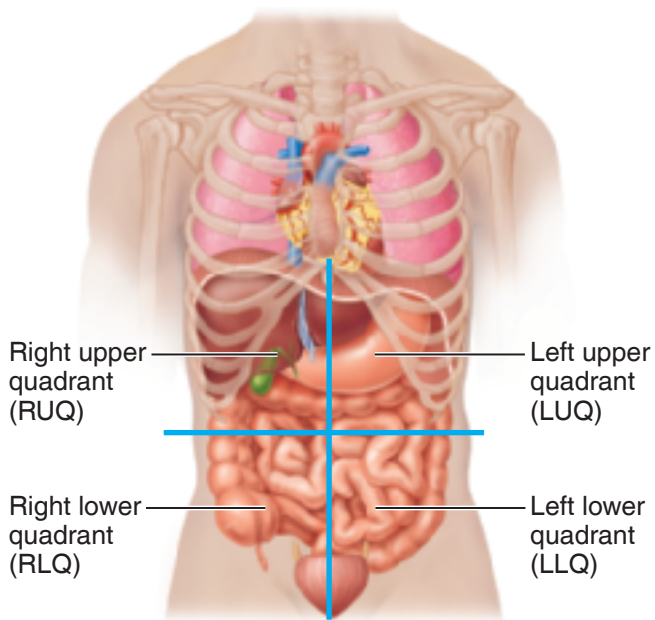


Figure 1.7 The four abdominopelvic quadrants.

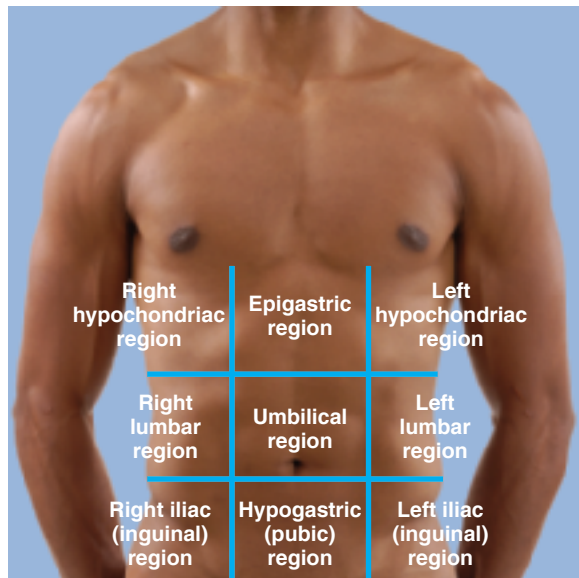
In this scheme used by medical personnel, the abdominopelvic cavity is divided into four quadrants by two planes.

- The **right lumbar region** and **left lumbar region** lie lateral to the umbilical region (*lumbus* = loins) and spinal column between the bottom ribs and the hip bones; see Figure 1.4b).
- The **right hypochondriac** (hi''po-kon'dre-ak) **region** and **left hypochondriac region** flank the epigastric region and contain the lower ribs (*chondro* = cartilage).

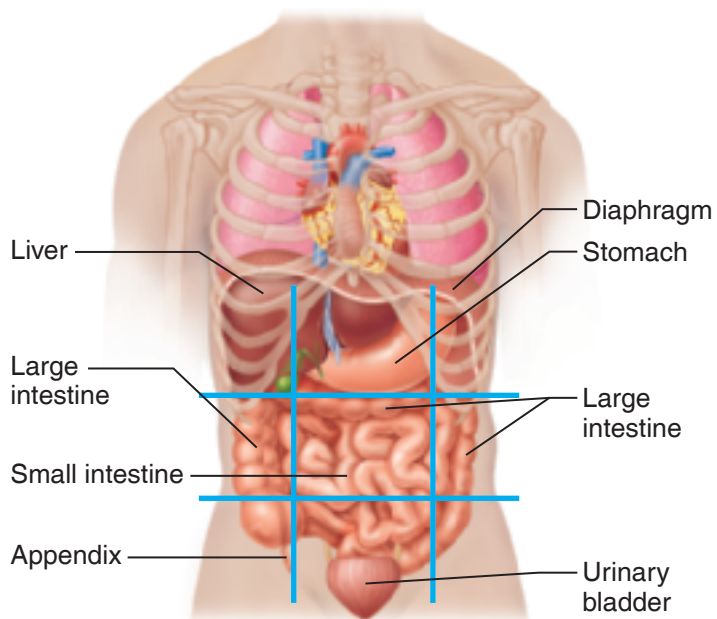
Other Body Cavities

In addition to the large closed body cavities, there are several smaller body cavities. Most are in the head and open to the body exterior.

- **Oral cavity and digestive cavity.** The oral cavity, or the mouth, contains the teeth and tongue. This cavity is part of and continuous with the digestive organs, which open to the exterior at the anus.
- **Nasal cavity.** Located within and posterior to the nose, the nasal cavity is part of the respiratory system.



(a) Nine regions delineated by four planes



(b) Anterior view of the nine regions showing the superficial organs

Figure 1.8 The nine abdominopelvic regions. The abdominopelvic cavity is divided into nine regions by four planes in this

scheme used mostly by anatomists. In **(a)**, the superior transverse plane is just superior to the ribs; the inferior transverse plane is just

superior to the hip bones; and the parasagittal planes lie just medial to the nipples.

- **Orbital cavities.** The orbital cavities (orbits) in the skull house the eyes and present them in an anterior position.
- **Middle ear cavities.** The middle ear cavities carved into the skull lie just medial to the eardrums. These cavities contain tiny bones that transmit sound vibrations to the hearing receptors in the inner ears.

Did You Get It?

11. If you were dissecting a cadaver and wanted to separate the thoracic cavity from the abdominal cavity, which type of section would you make?
12. Which of the following organs are in the abdominopelvic cavity: spinal cord, small intestine, uterus, heart?
13. Joe went to the emergency room, where he complained of severe pains in the lower right quadrant of his abdomen. What might be his problem?

For answers, see Appendix A.

Homeostasis

→ Learning Objectives

- Define **homeostasis**, and explain its importance.
- Define **negative feedback**, and describe its role in maintaining homeostasis and normal body function.

When you really think about the fact that your body contains trillions of cells in nearly constant activity, and that remarkably little usually goes wrong with it, you begin to appreciate what a marvelous organism your body really is. The word **homeostasis** (ho"me-o-sta'sis) describes the body's ability to maintain relatively stable internal conditions even though the outside world is continuously changing. Although the literal translation of *homeostasis* is "unchanging" (*homeo* = the same; *stasis* = standing still), the term does not really mean an unchanging state. Instead, it indicates a *dynamic* state of equilibrium, or a balance in which internal conditions change and vary but always within relatively narrow limits.

In general, the body demonstrates homeostasis when its needs are being adequately met and it is functioning smoothly. Virtually every organ system plays a role in maintaining the constancy of the internal environment. Adequate blood levels of vital nutrients must be continuously present, and heart activity and blood pressure must be constantly monitored and adjusted so that the blood is propelled with adequate force to reach all body tissues. Additionally, wastes must not be allowed

to accumulate, and body temperature must be precisely controlled.

Communication within the body is essential for homeostasis and is accomplished chiefly by the nervous and endocrine systems, which use electrical signals delivered by nerves or bloodborne hormones, respectively, as information carriers. The details of how these two regulating systems operate are the subjects of later chapters, but we explain the basic characteristics of the neural and hormonal control systems that promote homeostasis here.

Components of Homeostatic Control Systems

Regardless of the factor or event being regulated (this is called the *variable*), all homeostatic control mechanisms have at least three components: a *receptor*, *control center*, and *effector* (**Figure 1.9**). The **receptor** is a type of sensor that monitors and responds to changes in the environment. It responds to such changes, called *stimuli*, by sending information (input) to the second component, the control center. Information flows from the receptor to the control center along the *afferent pathway*. (It may help to remember that information traveling along the *afferent* pathway *approaches* the control center.)

The **control center** determines the level (set point) at which a variable is to be maintained. This component analyzes the information it receives and then determines the appropriate response or course of action.

The third component, the **effector**, provides the means for the control center's response (output) to the stimulus. Information flows from the control center to the effector along the *efferent pathway*. (*Efferent* information *exits* from the control center.) The results of the response then *feed back* to influence the stimulus (the original change), either by reducing the amount of change (negative feedback), so that the whole control mechanism is shut off; or by increasing the amount of change (positive feedback), so that the reaction continues at an even faster rate.

Feedback Mechanisms

Most homeostatic control mechanisms are **negative feedback** mechanisms, as indicated in Figure 1.9. In such systems, the net effect of the response to the stimulus is to either shut off the original stimulus or reduce its intensity. A good example of a nonbiological negative feedback

Q: If this control system were regulating room temperature, what apparatus would be the effector?

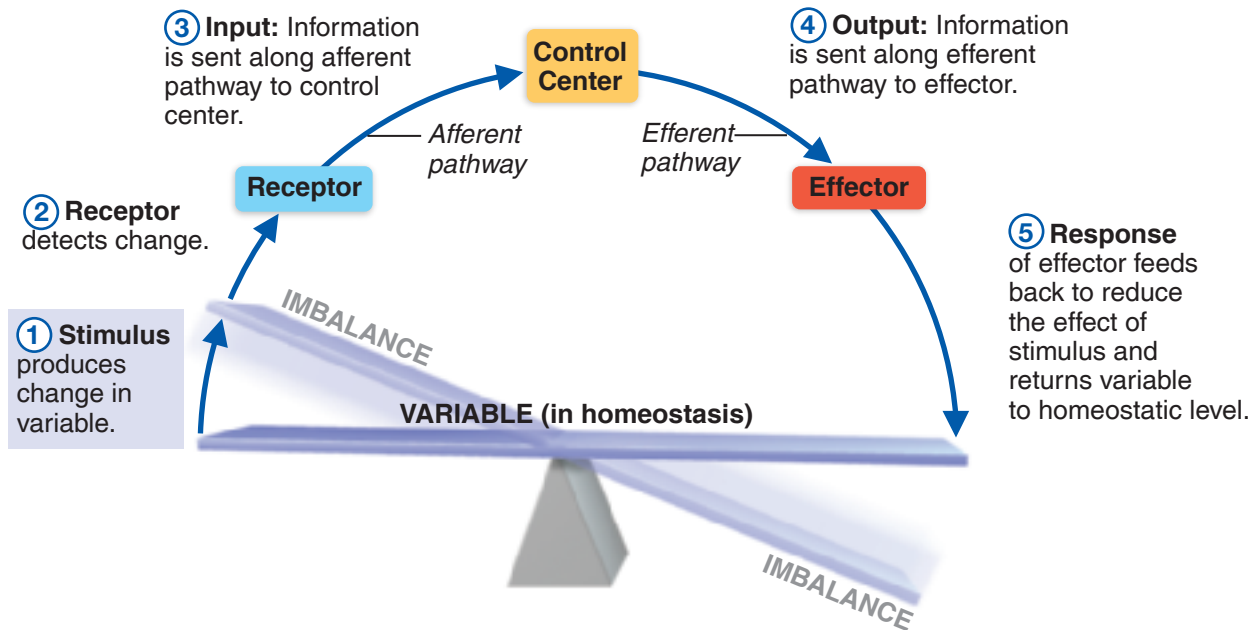


Figure 1.9 The elements of a homeostatic control system. Interaction between the receptor, control center, and effector is essential for normal operation of the system.

system is a home heating system connected to a thermostat. In this situation, the thermostat contains both the receptor and the control center. If the thermostat is set at 20°C (68°F), the heating system (effector) will be triggered ON when the house temperature drops below that setting. As the furnace produces heat, the air is warmed. When the temperature reaches 20°C or slightly higher, the thermostat sends a signal to shut off the furnace. Your body “thermostat” operates in a similar way to regulate body temperature. Other negative feedback mechanisms regulate heart rate, blood pressure, breathing rate, the release of hormones, and blood levels of glucose (blood sugar), oxygen, carbon dioxide, and minerals.

Positive feedback mechanisms are rare in the body because they tend to increase the original disturbance (stimulus) and to push the variable *farther* from its original value. Typically these mechanisms control infrequent events that occur explosively and do not require continuous adjustments. Blood clot-

ting and the birth of a baby are the most familiar examples of positive feedback mechanisms.

Homeostatic Imbalance 1.1

Homeostasis is so important that most disease can be regarded as being the result of its disturbance, a condition called **homeostatic imbalance**. As we age, our body organs become less efficient, and our internal conditions become less and less stable. These events place us at an increasing risk for illness and produce the changes we associate with aging.

We provide examples of homeostatic imbalance throughout this text to enhance your understanding of normal physiological mechanisms. _____+

Did You Get It?

- When we say that the body demonstrates homeostasis, do we mean that conditions in the body are unchanging? Explain your answer.
- When we begin to become dehydrated, we usually get thirsty, which causes us to drink liquids. Is the thirst sensation part of a negative or a positive feedback control system? Defend your choice.

A: The heat-generating furnace or oil burner.

For answers, see Appendix A.

Summary

An Overview of Anatomy and Physiology

(pp. 1–2)

1. Anatomy is the study of structure. Observation is used to see the sizes, shapes, and relationships of body parts.
2. Physiology is the study of how a structure (which may be a cell, an organ, or an organ system) functions or works.
3. Structure determines what functions can occur; therefore, if the structure changes, the function must also change.

Levels of Structural Organization (pp. 2–7)

1. There are six levels of structural organization. Atoms (at the chemical level) combine, forming the unit of life, the cell. Cells are grouped into tissues, which in turn are arranged in specific ways to form organs. An organ system is a group of organs that performs a specific function for the body (which no other organ system can do). Together, all of the organ systems form the organism, or living body.
2. Eleven organ systems make up the human body: the integumentary, skeletal, muscular, nervous, endocrine, cardiovascular, lymphatic, respiratory, digestive, urinary, and reproductive systems. (For a description of the organ systems naming the major organs and functions, see pp. 3–7).

Maintaining Life (pp. 7–10)

1. To sustain life, an organism must be able to maintain its boundaries, move, respond to stimuli, digest nutrients and excrete wastes, carry on metabolism, reproduce itself, and grow.
2. Survival needs include food, oxygen, water, appropriate temperature, and normal atmospheric pressure. Extremes of any of these factors can be harmful.

The Language of Anatomy (pp. 10–19)

1. Anatomical terminology is relative and assumes that the body is in the anatomical position (standing erect, with palms facing forward).
2. Directional terms
 - a. Superior (cranial, cephalic): above something else, toward the head.
 - b. Inferior (caudal): below something else, toward the tail.

- c. Anterior (ventral): toward the front of the body or structure.
 - d. Posterior (dorsal): toward the rear or back of the body or structure.
 - e. Medial: toward the midline of the body.
 - f. Lateral: away from the midline of the body.
 - g. Proximal: closer to the point of attachment.
 - h. Distal: farther from the point of attachment.
 - i. Superficial (external): at or close to the body surface.
 - j. Deep (internal): below or away from the body surface.
3. Regional terms. Visible landmarks on the body surface may be used to specifically refer to a body part or area. (See pp. 12–13 for terms referring to anterior and posterior surface anatomy.)
 4. Body planes and sections
 - a. Sagittal section: separates the body longitudinally into right and left parts.
 - b. Frontal (coronal) section: separates the body on a longitudinal plane into anterior and posterior parts.
 - c. Transverse (cross) section: separates the body on a horizontal plane into superior and inferior parts.
 5. Body cavities
 - a. Dorsal: well protected by bone; has two subdivisions.
 - (1) Cranial: contains the brain.
 - (2) Spinal: contains the spinal cord.
 - b. Ventral: less protected than dorsal cavity; has two subdivisions.
 - (1) Thoracic: The superior cavity that extends inferiorly to the diaphragm; contains heart and lungs, which are protected by the rib cage.
 - (2) Abdominopelvic: The cavity inferior to the diaphragm that contains the digestive, urinary, and reproductive organs. The abdominal portion is vulnerable because it is protected only by the trunk muscles. The pelvic portion is somewhat protected by the bony pelvis. The abdominopelvic cavity is often divided into four quadrants or nine regions (see Figures 1.8 and 1.9).
 - c. Smaller body cavities include the oral, nasal, orbital, and middle ear cavities. All are open to the outside of the body except the middle ear cavity.

Homeostasis (pp. 19–20)

1. Body functions interact to maintain homeostasis, or a relatively stable internal environment within the body. Homeostasis is necessary for survival and good health; its loss results in illness.
2. All homeostatic control mechanisms have three components: (1) a receptor that responds to environmental changes (stimuli) and (2) a control center that assesses those changes and produces a response by activating (3) the effector.

3. Most homeostatic control systems are negative feedback systems, which act to reduce or stop the initial stimulus. Some are positive feedback systems, which act to increase the initial stimulus, as in the case of blood clotting.

Review Questions

Access additional practice questions using your smartphone, tablet, or computer:
MasteringA&P® > Study Area > Practice Tests & Quizzes

Multiple Choice

More than one choice may apply.

1. Consider the following levels: (1) chemical; (2) tissue; (3) organ; (4) cellular; (5) organismal; (6) systemic. Which of the following choices has the levels listed in order of increasing complexity?
 - a. 1, 2, 3, 4, 5, 6
 - b. 1, 4, 2, 5, 3, 6
 - c. 3, 1, 2, 4, 6, 5
 - d. 1, 4, 2, 3, 6, 5
 - e. 4, 1, 3, 2, 6, 5
2. Which is *not* essential to survival?
 - a. Water
 - b. Oxygen
 - c. Gravity
 - d. Atmospheric pressure
 - e. Nutrients
3. Using the terms listed below, fill in the blank with the proper term.
 anterior superior medial proximal superficial
 posterior inferior lateral distal deep
 The heart is located _____ to the diaphragm.
 The muscles are _____ to the bone.
 The shoulder is _____ to the elbow.
 In anatomical position, the thumb is _____ to the index finger.
 The vertebral region is _____ to the scapular region.
 The gluteal region is located on the _____ surface of the body.

4. Match the proper anatomical term (column B) with the common name (column A) for the body regions listed below.

Column A

- ___ 1. buttocks
- ___ 2. back
- ___ 3. heel
- ___ 4. front of elbow
- ___ 5. toes
- ___ 6. groin
- ___ 7. forehead
- ___ 8. calf
- ___ 9. sole of foot

Column B

- a. inguinal
- b. frontal
- c. dorsal
- d. sural
- e. gluteal
- f. antecubital
- g. plantar
- h. digital
- i. calcaneal

5. Anatomical terms that apply to the backside of the body in the anatomical position include
 - a. ventral and anterior.
 - b. back and rear.
 - c. posterior and dorsal.
 - d. head and lateral.
6. A neurosurgeon orders a spinal tap for a patient. Into what body cavity will the needle be inserted?
 - a. Ventral
 - b. Thoracic
 - c. Dorsal
 - d. Cranial
 - e. Pelvic
7. Which of the following groupings of the abdominopelvic regions is medial?
 - a. Hypochondriac, hypogastric, umbilical
 - b. Hypochondriac, lumbar, inguinal
 - c. Hypogastric, umbilical, epigastric
 - d. Lumbar, umbilical, iliac
 - e. Iliac, umbilical, hypochondriac
8. Which of the following is (are) involved in maintaining homeostasis?
 - a. Effector
 - b. Control center
 - c. Receptor
 - d. Feedback
 - e. Lack of change

Short Answer Essay

9. Define *anatomy* and *physiology*.
10. List the 11 organ systems of the body, briefly describe the function of each, and then name two organs in each system.
11. Many body structures are symmetrical. Are the kidneys symmetrical? What about the stomach?
12. On what body surface is each of the following located: nose, calf of leg, ears, umbilicus, fingernails?



Critical Thinking and Clinical Application Questions

16. A nurse informed John that she was about to take blood from his antecubital region. What part of his body was she referring to? Later, she came back and said that she was going to give him an antibiotic shot in the deltoid region. Did he take off his shirt or his pants to get the shot? Before John left the office, the nurse noticed that his left sural region was badly bruised. What part of his body was black and blue?
17. Jennifer fell off her motorcycle and tore a nerve in her axillary region. She also tore ligaments in her cervical and scapular regions and broke the only bone of her right brachial region. Explain where each of her injuries is located.
18. Mr. Garcia is behaving abnormally, and doctors strongly suspect he has a brain tumor. Which medical imaging device—conventional X ray, CT, PET, ultrasound, or fMRI—would be best for precisely locating a tumor within the brain? Explain your choice.
19. Parathyroid hormone (PTH) is secreted in response to a drop in the calcium level in the blood. The secretion of PTH is regulated by a negative feedback mechanism. What can you expect to happen to the calcium blood level as increased amounts of PTH are secreted, and why?
20. Mr. Harvey, a computer programmer, has been complaining about numbness and pain in his right hand. His physician diagnosed carpal tunnel syndrome and prescribed a splint. Where will Mr. Harvey apply the splint? Be sure to use correct anatomical terminology in your answer.
21. Dan “threw out his back” after lifting heavy furniture and complained of pain radiating down the back of his right leg. Use anatomical terminology to describe the body regions where the injury occurred and where Dan experienced pain. Which imaging technique would you prescribe to diagnose a spinal problem? Explain your choice.
22. Billy was dicing vegetables for dinner and accidentally cut his finger. Which feedback system, positive or negative, is at work during the process of blood clotting? Explain your choice.
23. How is the concept of homeostasis (or its loss) related to disease and aging? Provide examples to support your reasoning.